

# Intraoperative assessment of right ventricular volume and function<sup>☆</sup>

Raffaele De Simone<sup>a,\*</sup>, Ivo Wolf<sup>b</sup>, Sibylle Mottl-Link<sup>a</sup>, Bernd W. Böttiger<sup>c</sup>,  
Helmuth Rauch<sup>c</sup>, Hans-Peter Meinzer<sup>b</sup>, Siegfried Hagl<sup>a</sup>

<sup>a</sup>Department of Cardiac Surgery, University of Heidelberg, Im Neuenheimer Feld 110, 69120 Heidelberg, Germany

<sup>b</sup>Department of Medicine and Biology Informatics, DKFZ (German Cancer Research Centre), Im Neuenheimer Feld 280, 69120 Heidelberg, Germany

<sup>c</sup>Department of Anaesthesiology, University of Heidelberg, Im Neuenheimer Feld 110, 69120 Heidelberg, Germany

Received 15 November 2004; received in revised form 9 January 2005; accepted 10 January 2005; Available online 7 March 2005

## Abstract

**Objective:** Right ventricular function is an important aspect of global cardiac performance which affects patients' outcome after cardiac surgery. Due to its geometrical complexity, the assessment of right ventricular function is still a very difficult task. Aim of this study was to investigate the value of a new technique for intraoperative assessment of right ventricle based on transesophageal 3D-echocardiography, and to compare it to volumetric thermodilution by using a new generation of fast response thermistor pulmonary artery catheters. **Methods:** Twenty-five patients with coronary artery disease underwent 68 intraoperative measurements by 3D-echocardiography and thermodilution simultaneously. Following parameters were analysed: right ventricular end-diastolic volume (RVEDV), end-systolic volume (RVESV) and ejection fraction (RVEF). Pulmonary, systemic and central venous pressures were simultaneously recorded. Segmentation of right ventricular volumes were obtained by the 'Coons-Patches' technique, which was implemented into the EchoAnalyzer<sup>®</sup>, a multitask system developed at our institution for three-dimensional functional and structural measurements. **Results:** Right ventricular volumes obtained by 3D-echocardiography did not show significant correlations to those obtained by thermodilution. Volumetric thermodilution systematically overestimates right ventricular volumes. Significant correlations were found between RVEF measured by 3D-echocardiography and those obtained by thermodilution ( $r=0.93$ ;  $y=0.2+0.80x$ ;  $SEE=0.03$ ;  $P<0.01$ ). Bland-Altman analysis showed that thermodilution systematically underestimates RVEF. The bias for measuring RVEF was +15.6% with a precision of  $\pm 4.3\%$ . The patients were divided into two groups according to left ventricular function. The group of patients with impaired function showed significantly lower right ventricular ejection fraction ( $44.1 \pm 4.6$  vs.  $55.1 \pm 3.9\%$ ;  $P<0.01$ ). **Conclusions:** Three-dimensional echocardiography provides a useful non-invasive tool for intraoperative and serial assessment of right ventricular function. This new technique, which overcomes the limitations of previous methods, may offer key insights into management and outcome of patients with severe impairment of cardiac function.

© 2005 Elsevier B.V. All rights reserved.

**Keywords:** Right ventricle; Ejection fraction; Monitoring; Transesophageal 3D echocardiography; Pulmonary artery catheter; Thermodilution; Cardiac surgery

## 1. Introduction

The influence of right ventricular function on patients' prognosis has been increasingly recognized as a consequence of the growing number of patients with severely impaired cardiac function who undergo heart surgery. Patients with impaired left ventricular function and right ventricular dysfunction show poor outcome after cardiac surgical procedures [1-3].

Up to now right ventricular function can be assessed by different methods: biplane angiography [4], radionuclide techniques [5], echocardiography [6,7], magnetic resonance imaging [8] and thermodilution [9,10].

However, only two techniques, like echocardiography and thermodilution can be applied to monitor right ventricular and global heart function during cardiac surgery and at the bedside. Aim of this study was to evaluate these two techniques for intraoperative assessment of right ventricle based on transesophageal three-dimensional echocardiography [11] and to compare these measurements to volumetric thermodilution obtained by using a new generation of fast response thermistor pulmonary artery catheters [9-12].

## 2. Methods

### 2.1. Patients

Twenty-five patients undergoing elective coronary artery bypass were included in this study. The mean age of patients (19 male, six female) was 64 years  $\pm 10.8$ , with a mean body

<sup>☆</sup> Presented at the joint 18th Annual Meeting of the European Association for Cardio-thoracic Surgery and the 12th Annual Meeting of the European Society of Thoracic Surgeons, Leipzig, Germany, September 12-15, 2004.

\*Corresponding author. Tel.: +49 6221 566395; fax: +49 6221 5655895.

E-mail address: [r.de.simone@urz.uni-heidelberg.de](mailto:r.de.simone@urz.uni-heidelberg.de) (R. De Simone).

weight of  $74.1 \pm 11.6$  kg. The time on cardiopulmonary bypass averaged  $89 \pm 38$  min, with a mean aortic cross-clamping time of  $49 \pm 20$  min. Approval of the local Committee on Ethics and written informed consent was obtained prior to surgery. One group of 26 patients who underwent magnetic resonance imaging prior to coronary artery bypass operation was used as a control group in order to measure left ventricular volumes and compare them to three-dimensional echocardiography.

## 2.2. Transesophageal echocardiography

Two-dimensional echocardiographic data were obtained using a 5.0 MHz multiplane transesophageal echo-probe (Model 21369 A, connected to SONOS 5500 Imaging System, Philips, Andover, Massachusetts, USA). The probe was advanced to mid-oesophageal level to visualize a modified transversal four-chamber view, which entirely visualizes right ventricle. At each point of measurement, three cardiac cycles were recorded for later evaluation. Multiplane echocardiographic data were processed by the EchoAnalyzer<sup>®</sup>, a multitask system developed at our institution for three-dimensional reconstruction and measurements [13-15].

Right and left ventricular volumes were calculated by using the 'Coons-patches' technique [16] for segmentation of heart cavities, which was implemented into the EchoAnalyzer<sup>®</sup>. The proposed method enables to quickly extend segmentations performed on intersecting slices of arbitrary orientation to a three-dimensional surface model by means of interpolation with specialized 'Coons-patches' (Fig. 1). The described approach considerably reduces time

required for user interaction to obtain the object's shape and volume.

Right and left ventricular ejection fraction were estimated according to the equation

$$EF = (EDV - ESV/EDV) \times 100\%.$$

## 2.3. Volumetric thermodilution

Preoperatively, an arterial catheter was placed in the left radial artery, with pressure transducers being positioned at mid-thoracic level. Additionally, we introduced the new pulmonary artery catheter (7.5F CEDV-PAC, model 744H, Baxter Healthcare Corporation, Irvine, CA, USA), which interfaced with a computerized monitoring system (Vigilance<sup>™</sup> CCO/SvO<sub>2</sub>/CEDV Monitor, Baxter Healthcare Corporation, Irvine, CA, USA) and an additional ECG monitor in order to assess RR-intervals. With this new pulmonary artery catheter, modified pulsed warm thermodilution technique is clinically applicable: a computer-controlled thermal filament, mounted on the catheter, is placed in the right ventricle and randomly transfers 'boli' of heat (limited to 7.5 W and 44.0 °C) to the blood. The resulting changes in blood temperature are recorded with a distally mounted fast response thermistor. Based on simultaneously assessed RR-intervals, diastolic plateaus of the thermodilution curve are identified. This is necessary as the total end-diastolic heat mass in the right ventricle is the result of the heat mass at the end of the previous systole and of cooling effects due to the influx of colder blood during diastolic filling. These relations are summarised in the equation:

$$RVEF = (EDV - ESV)/EDV = 1 - [(T_{B2} - T_{B0})/(T_{B1} - T_{B0})].$$

Where:

- $T_{B0}$  blood temperature before heat application
- $T_{B1}$  blood temperature at  $T_1$  (during systole 1)
- $T_{B2}$  blood temperature at  $T_2$  (during systole 2)
- ESV end-systolic volume
- EDV end-diastolic volume

RVEF can be calculated having measured blood temperature before heat application and the decrease in blood temperature during a predefined period ( $T_1$  to  $T_2$ ).

Significant tricuspid valve regurgitation and intracardiac shunt, which may affect thermodilution measurements were ruled out by transesophageal echocardiography.

## 2.4. Study protocol

Measurements were carried out at three time points: before skin incision, 30 min after weaning from cardiopulmonary bypass, and postoperatively 2 h after the admission to the intensive care unit. Next to right ventricular ejection fraction, heart rate (HR), central venous pressure (CVP), mean arterial blood pressure (MAP), pulmonary capillary wedge pressure (PCWP), mean pulmonary artery pressure (MPAP) and pulmonary vascular resistance (PVR) were measured.

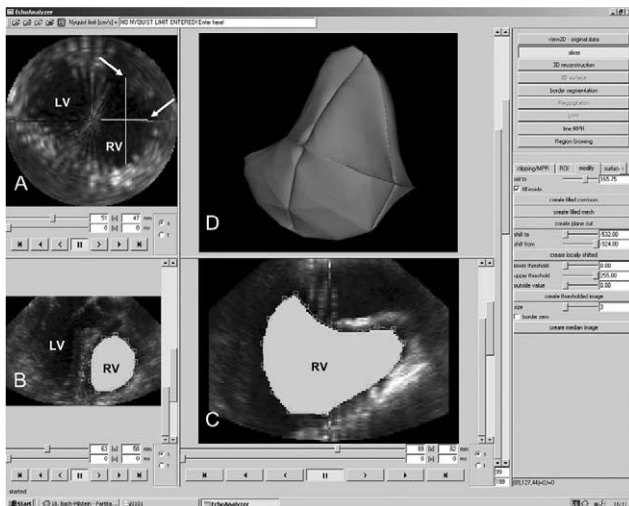


Fig. 1. Segmentation procedure of right ventricular cavity volume by the EchoAnalyzer<sup>®</sup>, a multitask system developed at our institution for 3D reconstruction and measurements of echocardiographic datasets. Panels A, B and C show the original echo data of right ventricle in three orthogonal planes. In panels B and C right endocardial contours are outlined as white areas (RV). In panel A these two areas can be seen (arrowheads). Panel D shows the correspondent 3D reconstruction of right ventricular volume obtained by the segmentation of three non-parallel slices. RV, right ventricle; LV, left ventricle.

Table 1  
Hemodynamic parameters

Parameters	Pre-CPB	Post-CPB	Post-OP	All measurements
HR (bpm)	58.8±16.9	86.2±12.3	92.8±19.2	79.3±20.2
CVP (mmHg)	7.5±2.6	7.3±2.2	7.8±2.5	7.5±2.4
MAP (mmHg)	78.5±14.0	76.4±11.2	73.8±13.3	76.3±12.8
PCWP (mmHg)	9.8±3.5	10.6±4.3	10.3±3.3	10.2±3.7
MPAP (mmHg)	20.0±5.0	20.0±4.1	19.7±4.9	19.9±4.6
PVR (dyn s/cm <sup>5</sup> )	140.2±34.4	138.2±33.8	139.5±31.6	139.3±33.3
RVEDV <sub>3D-Echo</sub> (%)	139.4±25.8	131.3±20.3	134.9±25.2	135.1±23.5
RVESV <sub>3D-Echo</sub> (%)	70.1±15.9	68.8±14.8	68.3±17.7	69.2±15.7
RVEF <sub>3D-Echo</sub> (%)	48.4±6.3%	47.6±8.0%	49.3±6.1%	48.9±7.0%
RVEDV <sub>Thermodilution</sub> (%)	198.8±39.4	188.8±30.6	199.4±37.0	195.0±35.4
RVESV <sub>Thermodilution</sub> (%)	130.5±31.0	125.3±24.6	137.3±32.9	131.0±29.0
RVEF <sub>Thermodilution</sub> (%)	34.4±8.1%	33.5±8.9%	31.6±7.1%	33.1±8.0%

Heart rate (HR), central venous pressure (CVP), mean arterial blood pressure (MAP), pulmonary capillary wedge pressure (PCWP), mean pulmonary artery pressure (MPAP) and pulmonary vascular resistance (PVR), right ventricular end diastolic volume (RVEDV<sub>3D-Echo</sub>), end systolic volume (RVESV<sub>3D-Echo</sub>), and ejection fraction (RVEF<sub>3D-Echo</sub>) assessed by 3D-Echo, right ventricular end diastolic volume (RVEDV<sub>Thermodilution</sub>), end systolic volume (RVESV<sub>Thermodilution</sub>), and ejection fraction (RVEF<sub>Thermodilution</sub>) assessed by thermodilution. Time points of measurements. Pre-CPB, measurements obtained prior to cardio-pulmonary bypass; Post-CPB, measurements obtained after cardio-pulmonary bypass; Post-OP, measurements obtained postoperatively. All data are presented as mean±SD.

## 2.5. Statistics

All results are presented as mean±SD, and *P* values <0.01 were considered statistically significant. Linear regression analysis was used to describe the correlations between different methods for assessing right ventricular volumes and function. Differences between groups with and without impaired cardiac function were assessed by Student's *t* test for unpaired data. The method of Bland and Altman [17] was used for the agreement of different diagnostic methods. Differences were considered statistically significant at a value of *P*<0.01.

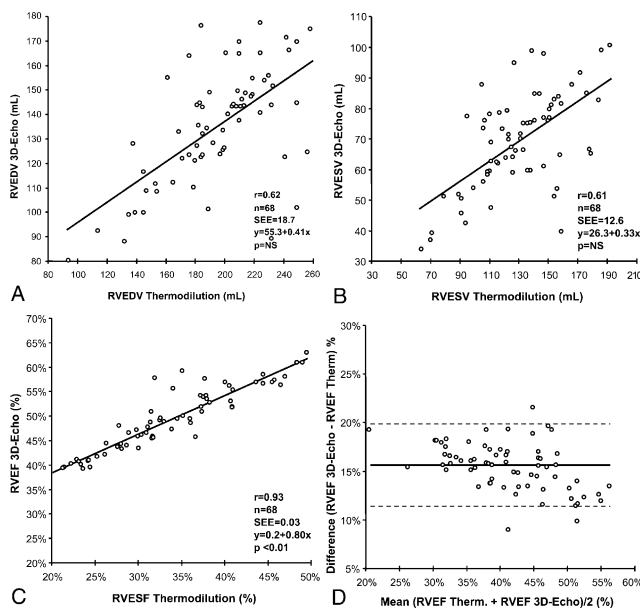


Fig. 2. Regression analyses of left ventricular enddiastolic (panel A), endsystolic (panel B) volumes and ejection fraction (panel C) between three-dimensional echocardiography vs. magnetic resonance imaging. Panel D shows bias analysis (Bland and Altman plot) comparing transesophageal echocardiography and pulmonary artery catheterization in the assessment of right ventricular ejection fraction.

## 3. Results

Volumetric thermodilution overestimated right ventricular volumes (Table 1). Although no correlation was found between right ventricular volumes obtained by thermodilution and those obtained by three-dimensional echocardiography (Fig. 2), right ventricular ejection fraction measured by these two techniques showed significant correlation ( $r=0.93$ ;  $y=0.2+0.80x$ ;  $SEE=0.03$ ;  $P<0.01$ ). Bland-Altman analysis showed that thermodilution systematically underestimates right ventricular ejection fraction. The bias for measuring right ventricular ejection fraction was +15.6% with a precision of ±4.3% (Fig. 2D).

In the group of patients who underwent magnetic resonance imaging left ventricular volumes and ejection fraction obtained by three-dimensional echocardiography showed significant correlations to those obtained by magnetic resonance imaging (Table 2).

The patients were divided into two groups according to left ventricular function as judged by ejection fraction obtained by planimetry of left ventricular angiography. Fourteen patients with ejection fraction ≤30% were assigned to the group with impaired function. Eleven

Table 2  
Linear regression analyses of ventricular volumes and ejection fraction

	<i>r</i>	$y=a+bx$	SEE	<i>P</i>
LVEDV (3D-Echo vs. MRI)	0.95	$y=40.4+0.79x$	10.5	<0.001
LVESV (3D-Echo vs. MRI)	0.97	$y=19.5+0.86x$	8.57	<0.001
LVEF (3D-Echo vs. MRI)	0.92	$y=0.0+0.84x$	0.05	<0.001
RVEDV (3D-Echo vs. Thermodilution)	0.62	$y=55.3+0.41x$	18.7	NS
RVESV (3D-Echo vs. Thermodilution)	0.61	$y=26.3+0.33x$	12.6	NS
RVEF (3D-Echo vs. Thermodilution)	0.93	$y=0.2+0.80x$	0.03	<0.01

Correlations between 3D-echocardiography vs. magnetic resonance imaging (MRI).

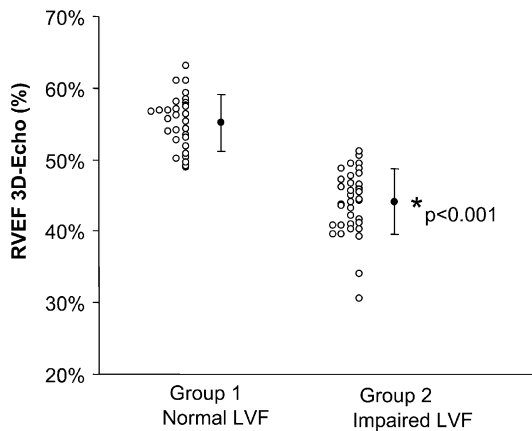


Fig. 3. Scatterplot showing comparison of right ventricular ejection fraction in two groups of patients according to left ventricular function. The group of patients with impaired function shows significant lower right ventricular ejection fraction ( $44.1 \pm 4.6$  vs.  $55.1 \pm 3.9\%$ ;  $P < 0.01$ ) than the group of patients with normal function. Individual and mean  $\pm$ SD values for each angiographic group are shown. \* $P < 0.01$ .

patients with normal left ventricular function had an ejection fraction  $> 30\%$ . The group of patients with impaired function showed significantly lower right ventricular ejection fraction ( $44.1 \pm 4.6$  vs.  $55.1 \pm 3.9\%$ ;  $P < 0.01$ ) than the group of patients with normal function (Fig. 3).

The time required for acquiring a complete three-dimensional dataset by transesophageal echocardiography ranged from 4 min and 20 s to 1 min and 45 s (mean: 2 min and 55 s), depending on the heart rhythm and rate. Processing time for semiautomatic segmentation of right ventricular contours ranged from 1 min and 10 s to 7 min and 26 s (mean: 3 min and 15 s) depending on the image quality and on the number of slices analysed. Computer processing time for obtaining right ventricular volumes and ejections was irrelevant, being only few milliseconds.

#### 4. Discussion

The importance of right ventricle for optimal patient management has been neglected previously. Right ventricular dysfunction plays a relevant role in a variety of conditions, which affect patients' prognosis since it is often associated with a distinct clinical syndrome requiring specific management. Right ventricular dysfunction is present in at least one third of patients with inferior myocardial infarction and is associated with a significant increase in mortality [18]. In most congenital heart diseases right ventricle is subjected to the effects of both volume and pressure overload, which is relevant to surgical corrective procedures. In tetralogy of Fallot, tricuspid atresia and Ebstein's anomaly the assessment of right ventricular volume has been shown to provide prognostic information [19]. The assessment of right ventricular function is also relevant to orthotopic heart transplantation, since in the early preoperative period an elevated pulmonary vascular resistance may produce right ventricular dilatation and tricuspid valve regurgitation, which is responsible for some early deaths [20,21].

Due to its geometrical complexity, the assessment of right ventricle, is still today a very difficult task. Whereas left ventricular cavity approximates to an ellipsoid model the main body of right ventricle is crescentic with separate inflow and outflow portions. Since right ventricle cannot be represented by any geometric model, its volume can poorly be calculated by any approximation.

In this study we demonstrated that intraoperative assessment of right ventricular volume by means of thermodilution and three-dimensional echocardiography is feasible and that these techniques are able to provide a useful estimation of right ventricular function, which is promptly available in the operating room.

The lack of correlation between right ventricular volumes obtained by thermodilution and those obtained by three-dimensional echocardiography does not surprise, since it is fundamentally due to the fact that thermodilution can only estimate cardiac volumes by approximation. This is confirmed by the extremely high values of end-diastolic and end-systolic volumes measured by thermodilution technique.

Despite the lack of correlation between right ventricular volumes, the presence of significant agreement between the right ventricular ejection fraction shows that these two methods can be reliably used for serial measuring of right ventricular function during heart surgery, which makes this valuable information available for surgical decision making.

In order to assess the differences of right ventricular ejection fraction in patients with impaired and those with preserved left cardiac function, we classified the patients into two groups as defined by angiographic measurements of left ventricular ejection fraction. Three-dimensional echocardiography revealed that in the group of patients with impaired left function, right ventricular ejection fraction also was lower than in those with preserved left function (Fig. 3). Serial intraoperative assessments of right ventricular function are needed to investigate the prognostic value of this parameter and its impact on surgical decision making in the different surgical procedures.

It is now generally accepted that magnetic resonance imaging is the gold standard technique for non-invasive estimation of ventricular volumes, however, its availability is limited by the induction of strong magnetic fields that prevent its application in the operating room. On the contrary, transesophageal echocardiography is now routinely available in the operating room for intraoperative preoperative assessment of the heart surgery [22]. The interpretation of our results is based on the finding that left ventricular volumes by three-dimensional echocardiography showed good correlations to those measured by magnetic resonance imaging (Table 2) and on the assumption that the assessment of right ventricular volumes by three-dimensional echocardiography showed the same good correlation. In fact, we assumed that the right ventricular volumes measured by three-dimensional echocardiography was the reference method to compare volumetric thermodilution to. As a matter of fact, the lack of a gold standard for direct comparison of right ventricular volumes to magnetic resonance imaging is the main limitation of this study. The postulation that three-dimensional echocardiography is



able to measure right ventricle as accurately as left ventricle, even if very suggestive, is based on indirect evidence (Table 2). The statistical analysis shows a significant correlation and agreement, but in reality the fact that thermodilution overestimates right ventricular volumes is rather based on the comparison to findings from the literature [7-9], and on the anatomical knowledge that enddiastolic volume of right ventricle is closer to the value measured by three-dimensional echocardiography ( $135.1 \pm 23.5$  ml) than that obtained by thermodilution ( $195.0 \pm 35$  ml).

A direct comparison of three-dimensional echocardiography to magnetic resonance imaging was beyond the design of this study, which main purpose was to compare intra- and peri-operative techniques for measuring right ventricular function, whereas magnetic resonance imaging cannot be applied in the operating theatre.

Another factor that may affect the assessment of right and left ventricular function is the influence of loading conditions. In the present study each pair of measurements (echocardiography and thermodilution) were obtained simultaneously, under the same loading conditions.

An important innovative approach of this study was the application of the 'Coons-patches' technique which allowed the quick three-dimensional reconstruction of transesophageal echocardiographic data. The 'Coons-patches' technique is a method primarily developed for Computer-Aided Design at the Massachusetts Institute of Technology [16]. This method has been modified and integrated in our system EchoAnalyzer, a multitask developed for analyzing three-dimensional data at our institution [13-15]. The fundamental advantages of this technique are the ability of interactive segmentation which may lead to improvements by additional slices; the segmentation on non-parallel slices avoids inconsistencies; the interpolation with Coons-patches requires a processing time shorter than 1 s; a significant reduction of number of slices can be achieved by this technique (Fig. 4). Except for very rare cases, automatic methods cannot guarantee to provide the correct segmentation, i.e. the identification of endocardial borders. Display and processing two-dimensional data (slices) are more precise than in three-dimensional datasets. One of the major issue of all three-dimensional methods of obtaining volumes is the inconsistency between the different slices obtained by tracing endocardial contours manually. This limitation has been overcome by the Coons-patches technique, since the use of contours in more than one orientation helped to avoid inconsistencies between neighbouring slices. In addition, this technique enables to rebuild and improve an existing three-dimensional volume by adding new additional slices (Fig. 4). The proposed method enabled to quickly extend segmentations performed on intersecting slices of arbitrary orientation to a three-dimensional surface model by means of interpolation with specialized 'Coons patches'. In summary, the described approach considerably reduced the time required for user interaction to obtain an accurate approximation of the complex right ventricular shape. The concept of segmenting in two-dimensional, non-parallel slices therefore has the potential of a wide user acceptance. One of the major advantage of the Coons-patches technique is the ability of obtaining ventricular volume and ejection

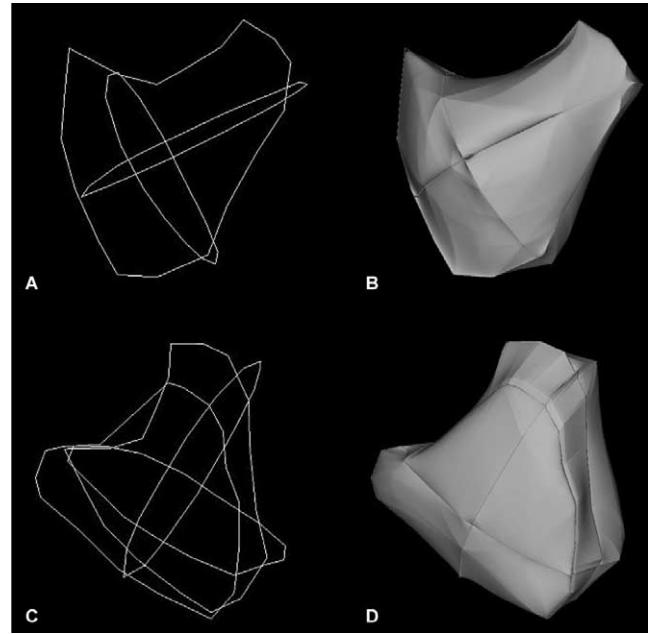


Fig. 4. Left panels (A and C) show non-parallel slices of right ventricular endocardial borders. Right panels (B and D) show the correspondent 3D reconstruction of right ventricular volumes. This figure demonstrates that the volume of right ventricle can be obtained by just three orthogonal endocardial borders (panels A and B). Additional slices do not noticeably change the shape of right ventricle (panels C and D).

fraction by a very fast processing time. The time required by this technique is almost exclusively due to the acquisition of a complete three-dimensional dataset; in the next future this acquisition will be further fastened by the advent of realtime three-dimensional echocardiography, which will reduce the acquisition to the time needed to obtain one single heart beat.

Up to now the state of the art of the echocardiographic assessment of right ventricle is the measurement of cross-sectional contraction area by two-dimensional echocardiography, postulating that fractional area change represents contractility of the entire ventricle [3]. It has been proven that regional differences exist in the extent of fibre shortening and contribution to stroke volume between different components of right ventricle contraction-relaxation sequence of the inflow portion preceding that of the infundibulum [23]. The finding of relatively high values for endsystolic right ventricular volumes may be due to the rather slow temporal resolution of ultrasound recordings (today ranging from 12 to 24 frames per second) that could be unable to detect such slight differences in the contraction-relaxation sequence of the right ventricle. The recent advent of faster echocardiographs (up to 100 frames per second) may improve the accuracy of these measurements. Furthermore, the advent of real-time three-dimensional echocardiography [24] has a big potential for providing the beat-to-beat changes in ventricular volumes which are needed for constructing volume-pressure relationships, and hence for better describing the contractility of right and left ventricle.

## 5. Conclusion

Three-dimensional echocardiography with the 'Coons-patches' technique and volumetric thermodilution provide readily accessible tools for intraoperative assessment of right ventricular function. Although these techniques are still under development, this investigation shows new perspectives for serial perioperative assessment of right ventricle which may improve the clinical management of patients with impaired cardiac function.

## Acknowledgements

This work was supported by the Deutsche Forschungsgemeinschaft within the SFB 414 'Information Technology in Medicine—Computer and Sensor Supported Surgery'.

## References

- [1] Maslow AD, Regan MM, Panzica P, Heindel S, Mashikian J, Comunale ME. Precardioplumony bypass right ventricular function is associated with poor outcome after coronary artery bypass grafting in patients with severe left ventricular systolic dysfunction. *Anesth Analg* 2002;95:1507-18.
- [2] Eddy AC, Rice CL, Anardi DM. Right ventricular dysfunction in multiple trauma victims. *Am J Surg* 1988;155:712-5.
- [3] Gorcsan J, Murali S, Counihan PJ, Mandarin WA, Kormos RL. Right ventricular performance and contractile reserve in patients with severe heart failure. Assessment by pressure-area relations and association with outcome. *Circulation* 1996;94:3190-7.
- [4] Ferlinz J. Measurements of right ventricular volumes in man from single plane cineangiograms. A comparison to the biplane approach. *Am Heart J* 1977;94:87-90.
- [5] Wackers FJ, Berger HJ, Johnstone DE. Multiple gated cardiac blood pool imaging for left ventricular ejection fraction: validation of the technique and assessment of variability. *Am J Cardiol* 1979;43:1159-66.
- [6] Kaul S, Tei C, Hopkins JM, Shah PM. Assessment of right ventricular function using two-dimensional echocardiography. *Am Heart J* 1984;107:526-31.
- [7] Ochiai Y, Morita S, Tanoue Y, Kawachi Y, Tominaga R, Yasui H. Use of transesophageal echocardiography for postoperative evaluation of right ventricular function. *Ann Thorac Surg* 1999;67:146-53.
- [8] Markiewicz W, Sechtem U, Higgins CB. Evaluation of the right ventricle by magnetic resonance imaging. *Am Heart J* 1987;113:8-15.
- [9] Jardin F, Brun-Ney D, Hardy A, Aegerter P, Beauchet A, Bourdarias JP. Combined thermodilution and two-dimensional echocardiographic evaluation of right ventricular function during respiratory support with PEEP. *Chest* 1991;99:162-8.
- [10] Böttiger BW, Soder M, Rauch H, Bohrer H, Motsch J, Bauer H, Martin E. Semi-continuous versus injectate cardiac output measurements in intensive care patients after cardiac surgery. *Intensive Care Med* 1999;22:312-8.
- [11] Jiang L, Handschumacher MD, Hibberd MG. Three-dimensional echocardiographic reconstruction of right ventricular volume: in vitro comparison with two-dimensional methods. *J Am Soc Echocardiogr* 1994;7:150-8.
- [12] Böttiger BW, Soder M, Rauch H, Bohrer H, Motsch J, Bauer H, Martin E. Semi-continuous versus injectate cardiac output measurements in intensive care patients after cardiac surgery. *Intensive Care Med* 1999;22:312-8.
- [13] De Simone R, Glombitza G, Vahl CF, Albers J, Meinzer HP, Hagl S. Three-dimensional color doppler for assessing mitral regurgitation during valvuloplasty. *Eur J Cardiothorac Surg* 1999;15:127-33.
- [14] Wolf I, De Simone R, Glombitza G, Meinzer HP. Echoanalyzer—a system for three-dimensional echocardiographic visualization and quantification. In: Computer assisted radiology and surgery. In: Proceedings of the 15th international symposium and exhibition. Amsterdam: Elsevier; 2001 p. 902-7.
- [15] Glombitza G, De Simone R, Wolf I, Heid V, Hagl S, Meinzer HP. Volumetric analysis and visualization of cardiologic ultrasound data. *Radiologie* 2000;40(2):168-75.
- [16] Coons SA. Surfaces for computer aided design of space forms. Massachusetts Institute of Technology. Technical Report: TR-41; 1967.
- [17] Bland JM, Altman DG. Statistical methods for assessing agreement between two methods of clinical measurement. *Lancet* 1986;1:307-10.
- [18] Zehender M, Kasper W, Kauder E. Right ventricular infarction as an independent predictor of prognosis after acute inferior myocardial infarction. *N Engl J Med* 1993;328:981-8.
- [19] Yetman AT, Freedom RM, McCrindle BW. Outcome in cyanotic neonates with Ebstein's anomaly. *Am J Cardiol* 1998;81:749-54.
- [20] Bathia SJ, Kirschenbaum JM, Shemin RJ. The evolving management of acute right-sided heart failure in cardiac transplant recipients. *J Am Coll Cardiol* 2001;38:923-31.
- [21] De Simone R, Lange R, Sack FU, Mehmanesh H, Hagl S. Atrioventricular valves insufficiency and atrial geometry after orthotopic heart transplantation. *Ann Thorac Surg* 1995;60:1686-93.
- [22] De Simone R, Lange R, Tanzeem A, Gams E, Saggau W, Hagl S. Intraoperative transesophageal echocardiography for the evaluation of mitral, aortic and tricuspid valve repair. A tool to optimize the surgical outcome. *Eur J Cardiothorac Surg* 1992;6:665-73.
- [23] Geva T, Powell AJ, Crawford EC, Chung T, Colan SD. Evaluation of regional differences in right ventricular systolic function by acoustic quantification echocardiography and cine magnetic resonance imaging. *Circulation* 1998;98:339-45.
- [24] Jenkins C, Bricknell K, Hanekom L, Marwick TH. Reproducibility and accuracy of echocardiographic measurements of left ventricular parameters using real-time three-dimensional echocardiography. *J Am Coll Cardiol* 2004;44:878-86.

## Appendix A. Conference discussion

**Dr J. Albes (Bernau, Germany):** Is there a possibility that tricuspid regurgitation significantly influences your model or the results of your model, let's say, in the absence or presence of significant tricuspid regurgitation?

**Dr De Simone:** In patients with impaired right ventricular function the dilatation of tricuspid annulus causes tricuspid regurgitation. I think that this does not influence the measurement of right ventricular volume.

I would like to add that we are trying to approach the quantification of tricuspid regurgitation in another way: since we are able to measure the flow in the pulmonary artery, as we can do with another method developed at our institution, we can measure the regurgitation as the difference of two stroke volumes. We are confident that with this method we can also achieve a more exact quantification of tricuspid regurgitation.

**Dr A. Wechsler (Philadelphia, PA, USA):** First, I wanted to be sure I understood. I saw you compared MRI versus the 3-D echo for the left ventricle. I didn't see it for the right ventricle. So I'm assuming that you're defining the gold standard as the echo. I don't know what you compared it to.

Second question is, is the timing predictable enough that with the Millar catheter in the right ventricle you could construct pressure volume loops if you were interested in studying contractility?

**Dr De Simone:** The second question first: of course, we are interested in studying volume pressures loops. We still need to synchronize the pressure signals to the volume measurements. I think that this technique has a good potential in order to make this.

Then, the first question: the comparison that we did with thermodilution is not possible since thermodilution is not the gold standard for measuring volumes. Of course, we assumed that on the basis of our previous validation on left ventricle volumes with MRI. And I also pointed out that, for example, one end-diastolic volume of 190 ml, as measured by thermodilution, is much too high to be comfortable with.